

Maurizio Cannata, Tommaso Grandi, Rawad Samarani, Luigi Svezia, Giovanni Grandi

A comparison of two implants with conical vs. internal hex connections: 1-year post-loading results from a multicentre, randomised, controlled trial

Key words complication, dental implant, conical connection, internal hex, peri-implant marginal bone levels

Purpose: To compare the clinical and radiological outcomes of identical implants with conical or internal hex connections.

Methods: A total of 90 patients with partial edentulism requiring one implant-supported prosthesis were randomly allocated in two equal groups ($n = 45$) to receive either implants with a conical connection or implants of the same type, but with an internal hex connection at three centres. Patients were followed for 1 year after loading. Outcome measures were implant failures, any complication and marginal bone level changes.

Results: One patient (2.2%) belonging to the internal hex group dropped out. One implant (2.2%) failed in the conical group. There were no statistically significant differences in implant failures between the two groups (2.2% vs. 0%, difference 2.2; 95% CI: -1.3; 5.7; $P = 0.315$). Two complications occurred in the conical group and two in the internal hex group ($P = 1.000$, difference 0.00, 95% CI: -3.1; 3.1). The 12-month peri-implant bone resorption was similar in both groups: 0.56 ± 0.53 mm (95% CI 0.03; 1.09) in the conical group and 0.60 ± 0.62 mm (95% CI 0.02; 1.22) in the internal hex group (difference = 0.04 ± 0.55 , 95% CI: -0.51; 0.59, $P = 0.745$).

Conclusions: Within the limitation of this study, preliminary short-term data (1 year post-loading) did not show any statistical differences between the two internal connection types, therefore clinicians could choose whichever connection they prefer.

Conflict of interest statement: Tommaso Grandi serves as consultant for J Dental Care, Modena, Italy. This study was completely self-financed and no funding was sought or obtained, not even in the form of free materials.



Maurizio Cannata, DDS
Private practice, Rende (Cosenza), Italy

Tommaso Grandi, DDS
Private practice, Modena, Italy

Rawad Samarani, DCD, DES
Assistant, Department of Periodontology, Saint-Joseph University, Beirut, Lebanon

Luigi Svezia, DDS
Private practice, Modena, Italy

Giovanni Grandi, MD
Department of Medical Sciences of Mother, Child and Adult, Obstetrics and Gynecology Unit, University of Modena and Reggio Emilia, Italy

Correspondence to:
Tommaso Grandi DDS,
Via Contrada 323, 41126 Modena, Italy
Email:
t.grandi@grandiclinic.com
phone: +39 3337095223

■ Introduction

The rehabilitation with oral implants is mainly based on the osseointegration concept, which refers to the direct structural and functional connection between newly formed bone and the surface of the implant¹. Stability of peri-implant bone is a prerequisite for long-term aesthetic and function of implant-supported restoration. Nevertheless, dental implants

are associated with some crestal bone remodelling². The implant-abutment connection is believed to play an important role in the outcome of the implant therapy. Bacterial leakage through the implant-abutment interface microgap and colonisation of the connection's inner portion determine the formation of the peri-implant chronic inflammatory infiltrate, thereby leading to bone resorption^{3,4}. Additionally, the literature shows that the

stress/strain concentration induced by an excessive, dynamic loading can trigger bone resorption, by bone microdamage accumulation around osseointegrated implants, even in the absence of an oral biofilm⁵. The implant-abutment connections more commonly used today are screw-retained and can be divided into two major groups: external and internal connections. The most widely used external connection is the 'external hexagon', originally used on the Branemark implant. However, mechanical problems including screw loosening and the research of a better aesthetic led to the development of internal connections⁶. The internal connection implants have been attracting attention in recent years leading to their being adopted for many implant systems and an increase in market share over other connections. Almost every manufacturer developed and modified the connection design claiming their products were better than the competition, but the two main internal connections are the conical and the internal hex ones. However, the clinical superiority of any of these connections has so far not been clearly confirmed by any well-designed and conducted clinical trial. Few studies investigated diverse connection types using diverse implant (e.g. macroscopic design, surface treatment), and patient-related (e.g. clinical situation) parameters^{6,7}. This makes it impossible to draw conclusions regarding clinical and bone loss differences. To the best of our knowledge, there are only two randomised controlled trials (RCTs) that evaluated clinical and radiographic parameters related to bone remodelling around implants using external hexagon and internal connection, but equal on all other implant- and patient-related parameters^{9,10}.

The aim of this randomised controlled trial was to compare the effectiveness of identical implants with conical connection vs internal hex connection in partially edentulous patients. The null hypothesis was that there would be no difference in success rates, complications and peri-implant marginal bone level changes between the two connections, against the alternative hypothesis of a difference. The present article is reported according to the CONSORT statement for improving the quality of reports of parallel group randomised trials (www.consort-statement.org/) and presents data up to 1 year after loading.

■ Materials and methods

Any patient with partial edentulism in the maxilla or mandible, requiring one implant-supported prosthesis, having a residual bone height of at least 10 mm and a thickness of at least 5 mm measured on computerised tomography (CT) scans, who was 18 or older and able to sign an informed consent form, was eligible for inclusion in this trial. Preoperative periapical radiographs were used for initial screening, followed by computer tomography scans to quantify the amount of bone precisely. Broad inclusion criteria were used, including any type of bone quality, any jaw location and if patients were heavy smokers. Patients were not allowed to take part for the following reasons:

1. General contraindications to implant surgery.
2. Subjected to irradiation in the head and neck area.
3. Treated or under treatment with intravenous amino-bisphosphonates.
4. Poor oral hygiene and motivation.
5. Untreated periodontitis.
6. Uncontrolled diabetes.
7. If they were pregnant or lactating.
8. Substance abusers.
9. A lack of opposite occluding dentition in the area intended for implant placement.
10. An acute or chronic infection at the site intended for implant placement.
11. Patients referred only for implant placement who could not be monitored at the treating centre.

All patients received detailed explanations and signed a written informed consent form prior to enrolment. They were then split into three groups according to whether they were non-smokers, moderate smokers (up to 10 cigarettes per day) or heavy smokers (more than 10 cigarettes per day). For patients needing more than one implant-supported prosthesis, the operator could choose which one to include in the study at the screening visit.

Patients were recruited and treated in three private dental practices by three operators (MC, TG and RS), who performed all the surgical and prosthetic interventions. Clinicians could choose the treatment option they considered best for the patient to be rehabilitated (i.e. flapless implant placement,

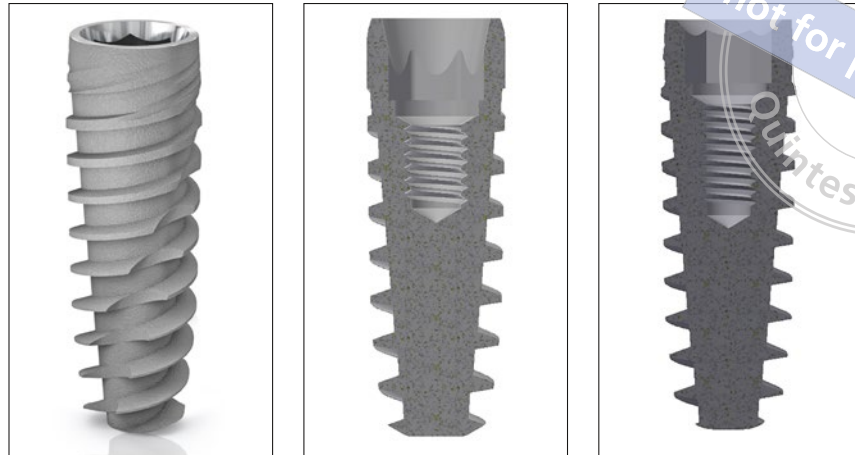


Fig 1 Characteristics of the implants used in the study; a) external macro-design of the implant; b) sagittal section showing the conical connection of JDIcon implant; c) sagittal section showing the internal hex connection of JDEvolution implant.

immediate post-extractive implants, submerged or non-submerged technique). Each clinician should have treated 30 patients.

The investigational devices were commercially-available tapered titanium screw-shaped dental implants with the same macrodesign and sand-blasted acid-etched surface up to the neck, but different prosthetic connection (JDIcon vs JDEvolution system, J Dental Care, Modena, Italy). The JDIcon implant is characterised by a 12 degree conical prosthetic interface with an interlocking hexagon in the bottom. The JDEvolution implant has a 2 mm deep internal hex and a 45-degree internal bevel (Figs 1a to 1c).

All patients underwent at least one session of oral hygiene instructions and professionally delivered debridement when required prior to the intervention. Anti-microbial prophylaxis was obtained with 1 g of amoxicillin and clavulanic acid (Augmentin, Roche SpA, Milan, Italy) every 12 hours from the day before surgery to the sixth postsurgical day. Patients allergic to penicillin were given 500 mg of clarithromycin (Klacid, Abbott SRL, Rome, Italy) 1 hr before the intervention and 250 mg twice a day for one week. On the day of surgery, patients were treated under local anaesthesia. When needed tooth extractions were performed as atraumatically as possible, to preserve the buccal alveolar bone. Extraction sockets were carefully cleaned of any granulation tissue. Individual clinicians could decided whether to elevate the flap or not. The implant site was prepared according to the implant manufacturer's recommendations. Once the implant site preparation was completed, the operator was told if the implants to be

placed had to be with conical or internal hex connection by opening a sequentially numbered sealed envelope corresponding to the patient recruitment number. Clinicians were free to decide to submerge or to leave the implants non-submerged for the healing period. Periapical radiographs (baseline) were made with the paralleling technique. Patients were prescribed chlorhexidine digluconate 0.2% mouthwash twice daily for 1 week post-surgery. After 3 months, all the implants underwent the standard prosthetic protocol and were loaded directly with definitive screw-retained or cemented restorations (Figs 2 and 3). The three operators involved in the trial (MC, TG and RS) made all clinical assessments, therefore outcome assessors were not blind. The primary outcome measures were:

- Implant failures, evaluated as implant mobility and removal of stable implants dictated by progressive marginal bone loss or infection. The stability of each implant was measured manually by tightening the abutment screw with a wrench delivering a torque of 30 Ncm, or by assessing the stability of single crowns using the metallic handles of two instruments. Spinning implants were recorded as failures.
- Complications: any biological and prosthetic complication occurred at the implant site during the entire follow-up time were recorded and reported per study group.

The secondary outcome measure was:

- Peri-implant marginal bone level changes: evaluated on intraoral radiographs taken with the paralleling technique at implant placement and

Fig 2 a) Periapical radiograph at implant placement of one JDI-con implant with conical connection included in this study; b) 1-year post-loading periapical radiograph.

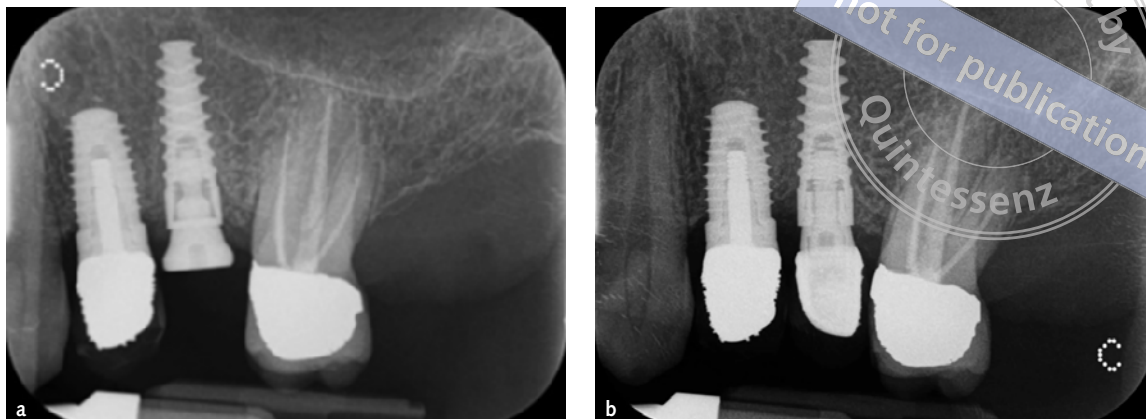
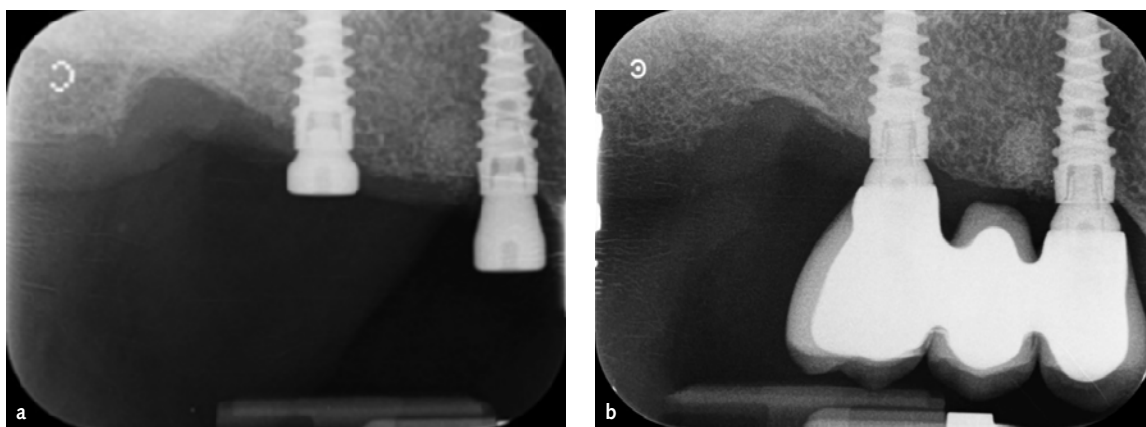


Fig 3 a) Periapical radiograph at implant placement of two JDEvolution implants with internal hex connection included in this study; b) 1-year post-loading periapical radiograph.



1 year after loading. All measurements were taken by an independent, blinded assessor (LS). Radiographs were scanned, digitised in JPG format, converted to TIFF format with a 600 dpi resolution and stored on a personal computer. Peri-implant marginal bone levels were measured using Image J 1.42 software (National Institute of Mental Health, Maryland, USA). The software was calibrated for every single image using the known implant diameter. Measurements of the mesial and distal crestal bone levels adjacent to each implant were made to the nearest 0.01 mm and averaged at patient level and then group level. The measurements were taken parallel to the implant axis. Reference points for the linear measurements were the most coronal margin of the implant collar and the most coronal point of bone-to-implant contact.

No sample size calculation was performed. During the protocol-formulation phase it was decided 30 patients should be recruited at each centre from a total of 90 patients, and 45 patients were

randomised to each group. The randomisation list was provided using computer generated random numbers, which were enclosed in sequentially numbered, opaque, sealed envelopes. The envelopes were opened only after the implant site was prepared, meaning treatment allocation was concealed from the investigators in charge of enrolling and treating the patients.

All data analysis was carried out according to a pre-established analysis plan. The patient was the statistical unit of the analyses. A doctor (GG) with expertise in dentistry analysed the data without knowing group allocation. Statistical analysis was performed using the statistical package StatView (version 5.01.98, SAS Institute Inc, Cary, NC, USA). Differences of mean at patient level for continuous outcomes between groups were compared by *t* test. Within-group comparison was performed with *t* test for paired data. The Student *t* test was used to evaluate differences in resorption between the two study groups. Comparisons among centres were performed by one-factor analysis of variance (ANOVA). Differences in the proportion of patients

Table 1 Subjects' and interventions' characteristics.

	Conical group (n=45) (%)	Internal hex group (n=45) (%)
Females	25 (55.6%)	22 (48.9%)
Mean age at implant insertion (range)	52.3 ± 16.8 (23-79)	51.2 ± 17.3 (25-75)
Smoking up to 10 cigarettes/day	9 (20.0%)	8 (17.8%)
Smoking more than 10 cigarettes/day	4 (8.9%)	6 (13.3%)
Implants inserted in mandibles	38/67 (57.8%)	40/72 (53.3%)
Implants inserted in incisor sites	7 (10.4%)	8 (11.1%)
Implants inserted in canine sites	4 (6%)	7 (9.7%)
Implants inserted in premolar sites	31 (46.3%)	29 (40.3%)
Implants inserted in molar sites	25 (37.3%)	28 (38.9%)
Mean implant length	10.4 ± 1.6	10.8 ± 1.8
Mean implant diameter	4.3 ± 0.8	4.1 ± 0.7
Hard bone quality at implant site	16 (23.9%)	14 (19.4%)
Medium bone quality at implant site	45 (67.1%)	47 (65.3%)
Soft bone quality at implant site	6 (9%)	11 (15.3%)
Post extractive implants	22 (32.8%)	31 (43.1%)
Implants inserted flapless	25 (37.3%)	36 (50.0%)
Patients with implants submerged	2 (4.4%)	3 (6.7%)
Single crowns	32 (71.1%)	28 (62.2%)
Partial fixed prostheses	13 (28.9%)	17 (37.8%)

with implant failures were compared among the centres using the chi-square test. Differences in crestal bone levels were compared among the centres using ANOVA. When necessary, prevalence of patient characteristics was compared by contingency tables and the chi-square test. All statistical comparisons were conducted at the 0.05 level of significance.

■ Results

Ninety patients were consecutively enrolled in the trial and randomised to the conical group and to the internal hex group; 45 patients for each group according to a parallel group design. All patients were treated according to the allocated interventions. Patients were recruited and operated on between February 2015 and July 2015. In total, 98 patients were screened for eligibility, but 8 were not included because they were referred only for implant placement. The follow-up focused on the time between implant placement and 1 year after loading. The main

baseline patients' features are reported in Table 1 and were similar in terms of sex, age, smoking, opposite dentition and bone quality. In total, 67 implants were inserted in the conical group and 72 implants were inserted in the internal hex group. One patient who randomised to the internal hex group (Dr Cannata) did not return for the delivery of the definitive crowns and was considered as a drop-out.

■ Implant failures

One out of 45 implants (2%) failed for infection in the conical group. The implant displayed post-operative pain, edema and signs of infection with pus. It was mobile 3 weeks after placement in a male, who was a heavy smoker. It was inserted as an immediate post-extractive implant in a premolar area in the maxilla and was successfully replaced after 4 months. There were no statistically significant differences in implant failures between the two groups (2.2% vs. 0%, difference 2.2; 95% CI: -1.3; 5.7; $P = 0.315$).

Table 2 Mean radiographic peri-implant marginal bone levels and changes between groups and time periods according to per protocol analysis.

	Implant placement	1 year after loading	Difference placement 1 year	P-value intra-group
	N Mean ± SD (95% CI)	N Mean ± SD (95% CI)	N Mean ± SD (95% CI)	
Conical group	45 0.03 ± 0.06 (-0.03; 0.09)	44 0.59 ± 0.61 (-0.02; 1.20)	44 0.56 ± 0.53 (0.03; 1.09)	0.0001
Internal hex group	45 0.02 ± 0.05 (-0.03; 0.07)	44 0.62 ± 0.65 (-0.03; 1.27)	44 0.60 ± 0.62 (0.02; 1.22)	0.0001
P-value intergroup	0.393	0.822	0.745	

Table 3 Comparison between the three different centres: each centre treated 30 subjects

	Grandi	Cannata	Samarani	P-value
Drop-out	0/30 (0%)	1/30 (3.3%)	0/30 (0%)	0.600
Patients with implant failure	1/30 (3.3%)	0/30 (0%)	0/30 (0%)	0.364
Patients with complications	2/30 (6.7%)	2/30 (6.7%)	0/30 (0%)	0.351
Bone loss	0.32 ± 0.51	1.19 ± 0.75	0.35 ± 0.58	0.0001

■ Complications

Four complications occurred in four patients, two in the conical group (postoperative pain and pus that determined implant removal 3 weeks after its placement; peri-implant mucositis at 8 months post-implantation, solved by a curettage and 0.2% chlorhexidine mouthwash); and two in the internal hex group (screw loosening of the final crown 2 months after loading; peri-implant mucositis at 10 months post-implantation, solved by a curettage and 0.2% chlorhexidine mouthwash). No statistical difference was found in complications between the two groups (4.4% vs. 4.4%, difference 0.0; 95% CI: -3.1; 3.1; $P = 1.000$) and the three different centres (6.7% vs. 6.7% vs. 0%, $P = 0.351$) – see Table 3.

■ Marginal bone level changes

At implant placement there was no statistically significant difference between the two treatment groups ($P = 0.395$). Bone levels were 0.03 ± 0.06 mm (95% CI -0.03; 0.09) for the conical group and 0.02 ± 0.05 mm (95% CI -0.03; 0.07) for the internal hex group. There was no statistically significant ($P = 0.824$) difference 1 year after loading between the two groups for peri-implant bone levels, 0.59 ± 0.61 mm (95% CI -0.02; 1.20) for the conical group and 0.62 ± 0.65 mm (95% CI -0.03;

1.27) for the internal hex group, and bone loss 0.56 ± 0.53 mm (95% CI 0.03; 1.09) for conical and 0.60 ± 0.62 (95% CI 0.02; 1.22) for internal hex group ($P = 0.743$; Table 2). Both treatment groups lost statistically significant marginal peri-implant bone at 1-year post-loading: $P = 0.0001$ for both conical and internal hex group.

By comparing the outcomes of the three different centres, no statistically significant differences were observed for drop-outs, failures or complications (Table 3). On the other hand, in the Cannata centre there was a significant superior bone loss ($+0.87$ mm, 95% CI 0.26; 1.48) in comparison to other centres ($P = 0.0001$), as shown in Table 3.

■ Discussion

This randomised controlled trial aimed to compare two implants with different prosthetic interfaces: conical versus internal hex connections. In order to perform a reliable evaluation, only the type of connection was different, all other implant characteristics (implant material, surface characteristics and macrodesign) remained exactly the same. At 1-year post loading, no statistically significant differences were observed; the number of complications was low and similar for both types. The implants in the conical group lost an average of 0.56 mm of peri-implant

bone while implants in the internal hex group lost about 0.60 mm. Due to the relatively small sample size of this study and moreover, the short follow-up (only 1 year after loading), it would be hazardous to conclude there are no differences between the two connection types. However no statistically or clinically significant differences were observed 1 year after loading. In order to draw more reliable conclusions, we need to wait for longer follow-ups, since the differences, which were not apparent at 1 year, may become evident over time.

It is widely debated that implant-abutment connection designs can induce different degrees of crestal bone remodelling, after being subjected to functional loading. In a randomised controlled split-mouth trial, comparing two implant designs with different prosthetic interfaces and neck configurations, Pozzi et al showed that marginal bone changes (loss) were statistically significantly different, with better results for the internal conical connection (0.51 mm), compared to external hex (1.10 mm)⁷. In another RCT, Pessoa et al observed significantly higher peri-implant bone loss for the external (1.14 mm), when compared with the internal (0.24 mm) abutment connection 1 year after loading⁹. Conversely Esposito et al comparing tapered titanium screw-shaped implants exhibiting external or internal connection did not observe any significant differences or even trends 5 years after loading¹⁰. Both implant types gradually lost marginal peri-implant bone; five years after loading, patients with external hex implants lost an average of 1.13 mm peri-implant bone versus 1.21 mm for patients with internal connection implants.

In previous studies, implant-abutment connection types have been compared between incongruous implant macro-designs and surface treatments in diverse clinical situations. As it was actually not only the implant-abutment connection type that varied, it is somewhat difficult to determine which factor had the highest contribution to the observed results.

Actually, according to the findings of this study, operators can choose the internal connection type according to their preferences. It could be also hypothesised that conical connections are more user-friendly for single implants or 2-unit implant-supported prostheses. On the contrary, it may be

that in the presence of multiple implants, the internal hex connection, going less deeply into the implant, could be more indicated to avoid the risk of impression distortion. However, these are simply hypotheses that need to be verified in further RCTs. There are no other published RCTs comparing conical versus internal hex connections, so meaningful comparisons with other similar RCTs cannot be made at the present stage. The major limitations of this study were the small sample size and the fact that the outcome measurements, except for radiographic assessments, were done by operators aware of patient allocation and who treated the patients themselves. Both implant types were tested under real clinical conditions and the patient inclusion criteria were rather broad, therefore the results of the present trial can be generalised to patients having similar characteristics.

■ Conclusions

No statistically or clinically significant differences were observed between the two types of internal connections 1 year after loading. Longer follow-up of wider patient populations are needed in order to draw more reliable conclusions since the differences, which were not apparent at 1 year, may become evident over time.

■ References

1. Branemark PI, Hansson BO, Adell R, Breine U, Lindstrom J, Hallen O, Ohman A. Osseointegrated implants in the treatment of the edentulous jaw. Experience from a 10-year period. *Scand J Plast Reconstr Surg Suppl* 1977; 16: 1–132.
2. Albrektsson T, Zarb G, Worthington P, Eriksson, RA. The long-term efficacy of currently used dental implants. A review and proposed criteria for success. *Int J Oral Maxillofac Implants* 1986; 132:11–25.
3. Hermann JS, Schoolfield JD, Schenk RK, Buser D, Cochran DL. Influence of the size of the microgap on crestal bone changes around titanium implants. A histometric evaluation of unloaded non-submerged implants in the canine mandible. *J Periodontol* 2001; 72:1372–1383.
4. King, GN, Hermann JS, Schoolfield JD, Buser D, Cochran DL. Influence of the size of the microgap on crestal bone levels in non-submerged dental implants: a radiographic study in the canine mandible. *J Periodontol* 2002; 73:1111–1117.
5. Duyck J, Rønold HJ, Van Oosterwyck H, Naert I, Vander Sloten J, Ellingsen JE. The influence of static and dynamic loading on marginal bone reactions around osseointegrated implants: an animal experimental study. *Clin Oral Implants Res* 2001; 12:207–218.

6. Gracis S, Michalakis K, Vigolo P, Vult von Steyern P, Zwahlen M, Sailer I. Internal vs external connections for abutments/reconstructions: a systematic review. *Clin Oral Implants Res* 2012;23:202–216.
7. Pozzi A, Tallarico M, Moy PK. Three-year post-loading results of a randomised, controlled, split-mouth trial comparing implants with different prosthetic interfaces and design in partially posterior edentulous mandibles. *Eur J Oral Implantol* 2014;7:47–61.
8. Felice P, Barausse C, Blasone R, Favaretto G, Stacchi C, Calvo M, Marin C, Buti J, Esposito M. A comparison of two dental implant systems in partially edentulous patients: 1-year post-loading results from a pragmatic multicentre randomised controlled trial. *Eur J Oral Implantol* 2014;7:397–409.
9. Pessoa RS, Sousa RM, Pereira LM, Neves FD, Bezerra FJ, Jacques SV, Sloten JV, Quirynen M, Teughels W, Spin-Neto R. Bone Remodeling Around Implants with External Hexagon and Morse-Taper Connections: A Randomized, Controlled, Split-Mouth, Clinical Trial. *Clin Implant Dent Relat Res* 2016 Jun 29. doi: 10.1111/cid.12437. [Epub ahead of print].
10. Esposito M, Maghaireh H, Pistilli R, Grusovin MG, Lee ST, Trullenque-Eriksson A, Gualini F. Dental implants with internal versus external connections: 5-year post-loading results from a pragmatic multicenter randomised controlled trial. *Eur J Oral Implantol* 2016;9:129–141.