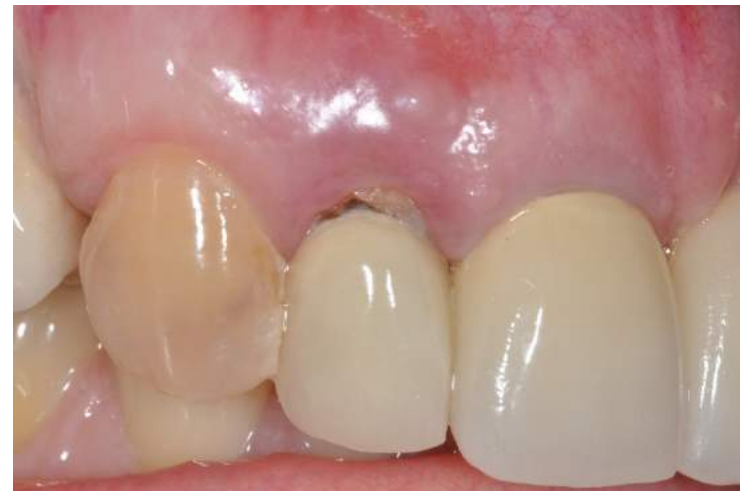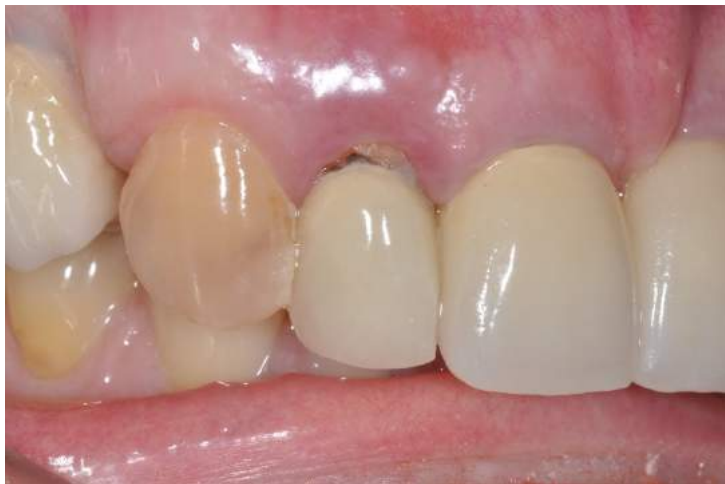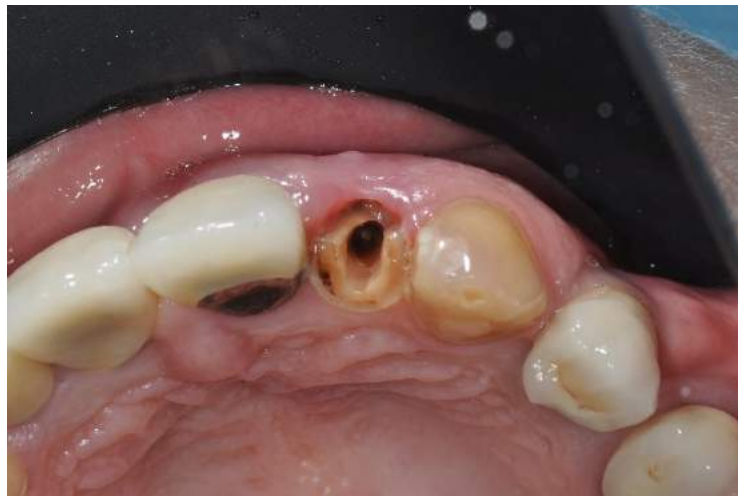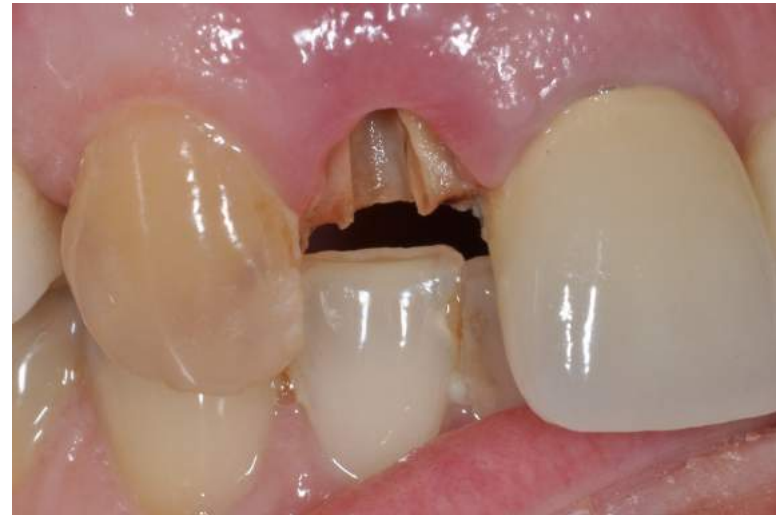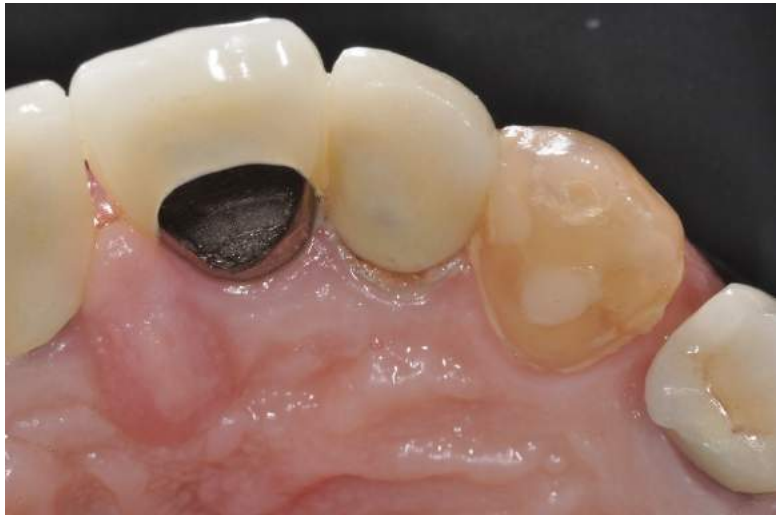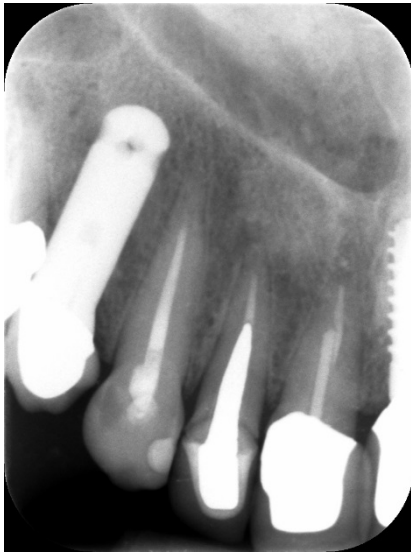


A 47 year old female patient came to the dental office complaining pain and swelling on upper right lateral incisor and mobility of the prosthetic crown on it.



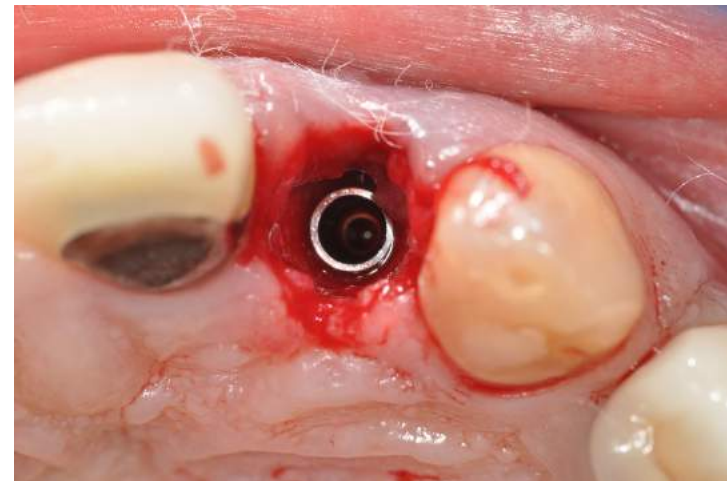
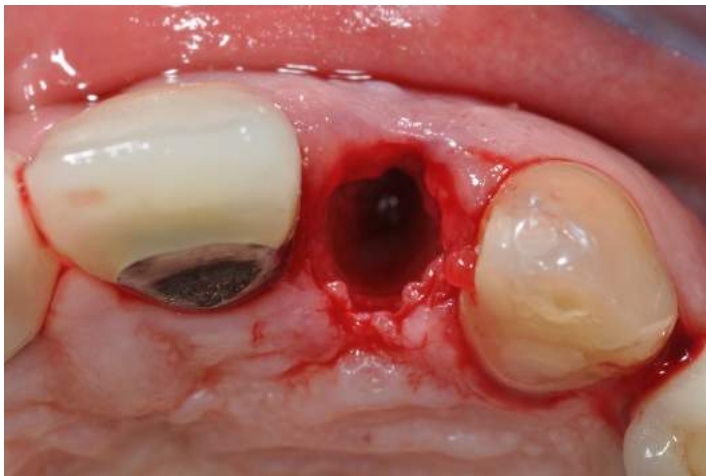Inspection showed the presence of vestibular fistula with about 9 mm periodontal probing. A deep vestibular root fracture was then diagnosed.



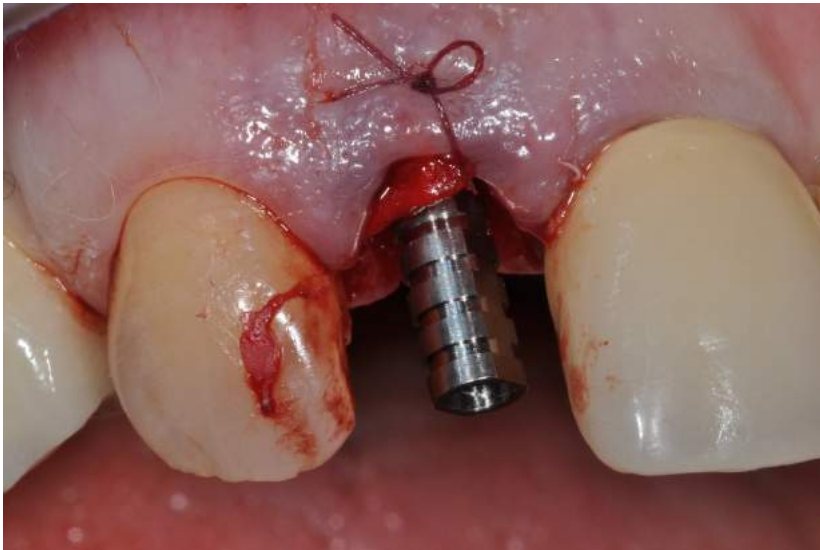


Pre-operative Xray

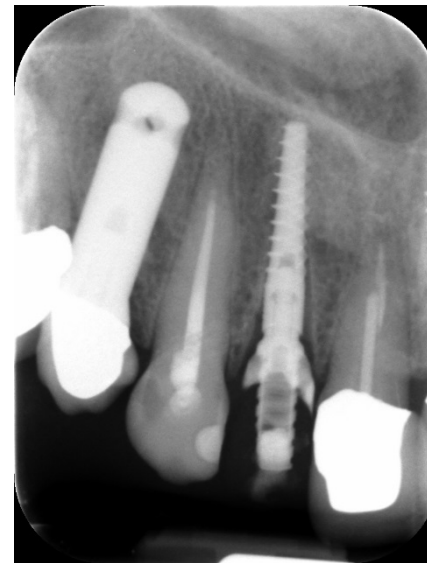The tooth was extracted and immediately replaced with a 2,75x15mm JDIcon Ultra-S implant

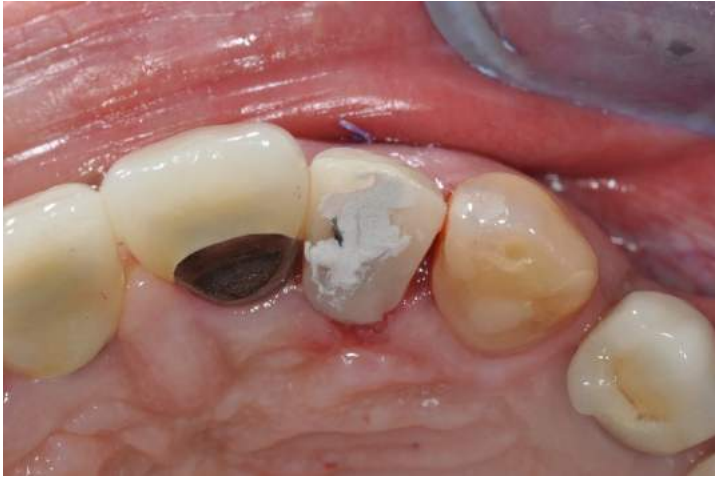

A temporary abutment was immediately attached to the implant.



Post-operative Xray





A not functionally loaded screw-retained temporary crown was placed.

